

## Esophageal intubation via a tracheoesophageal fistula - Type C

A. Lehavi<sup>1,4</sup>, N. Slijper<sup>2,4</sup>, A. Vachyan<sup>2,4</sup>, R. Steinberg<sup>2,4</sup>, T. Smolkin<sup>3,4</sup>

<sup>1</sup>Departments of Anesthesia, <sup>2</sup>Pediatric Surgery and <sup>3</sup>Neonatal Intensive Care, Rambam Healthcare Campus, Haifa, Israel

<sup>4</sup>Ruth and Bruce Rappaport Faculty of Medicine, Technion – Israel Institute of Technology, Haifa, Israel

Corresponding author: <sup>1</sup>A. Lehavi, Department of Anesthesia, Rambam Healthcare Campus, Haifa, Israel.

Email: amit.lehavi@gmail.com

### Keypoints

This case reports outlines the airway management of a neonate anesthetized for repair of esophageal atresia with tracheoesophageal fistula (TEF), in which the esophagus was initially intubated via the fistula. A more anatomically correct illustration of type C TEF is suggested.

### Abstract

Tracheal intubation and ventilation in neonates with esophageal atresia and tracheoesophageal fistula can be challenging, and may lead to catastrophic results if mismanaged. We present a case of a 2.2 Kg, otherwise well, full term neonate was scheduled for a thoracoscopic repair of a type C tracheoesophageal fistula. During tracheal intubation the endotracheal tube migrated into the esophagus, not enabling ventilation. We present possible immediate solutions for this rare emergency are, and a more anatomically accurate schematic drawing of type C tracheoesophageal fistula, possibly making the possibility of esophageal intubation via a fistula, as well as the management strategies better understood.

**Keywords:** Tracheoesophageal Fistula, Intubation, Neonate, Airway Management, Emergencies, Anesthesia

### Introduction

A neonate with a tracheoesophageal fistula may provide significant challenges to both the surgeon and the ane-

sthesiologist, some of which revolve around tracheal intubation and lung ventilation (1). The anesthetic technique and airway management requires deep understanding of the anatomic and physiologic basis of this condition (2).

### Case report

A one day old, 2.2Kg, otherwise well, full term neonate was scheduled for a thoracoscopic repair of a type C tracheoesophageal fistula diagnosed clinically and supported by a chest X-ray demonstrating the nasogastric tube curling in the proximal pouch.

Under full monitoring including invasive blood pressure general anesthesia was induced using 4% sevoflurane in oxygen. When relative loss of consciousness was achieved Rocuronium bromide (1.5 mg/Kg) was given intravenously, avoiding positive pressure ventilation.

Under direct laryngoscopy using a #0 Miller blade, a cuffed 3mm ID endotracheal tube (ETT) was passed between the vocal cords and advanced to 12cm at the lip. Manual ventilation through the ETT was initiated at a peak pressure of 20 cm of water but provided no end-

tidal CO<sub>2</sub> reading, minimal bilateral breath sound and significant gastric insufflation on auscultation.

Assuming the tip of the ETT is positioned cephalad to the fistula, the tube was gradually advanced to 15cm at the lip with no resistance under lung auscultation while ventilation continued. Significant gastric ventilation and minimal bilateral lung ventilation and no end-tidal CO<sub>2</sub> reading were noted. As blood oxygen saturation gradually decreased to 70%, the ETT was removed and mask ventilation with 100% oxygen was rapidly initiated while applying external pressure to the abdomen to minimize gastric dilatation, resulting in good chest expansion, minimal gastric dilatation and oxygen saturation rapid recovery to 100%.

Several options for this unusual behavior were suggested, including excessive pulmonary resistance leading to preferential gastric flow, esophageal intubation through a misdiagnosed type E fistula, traumatic false route, and esophageal intubation via a wide Type C fistula (3). As the last option seemed the most likely, a small roll was placed under the neonates' torso to direct the trachea anteriorly, and under direct laryngoscopy using a #0 Macintosh blade (to allow anterior shift of the larynx) a new cuffed 3mm ID ETT was passed between the vocal cords and advanced to 12cm at the lip, providing bilateral breath sounds, no gastric insufflation and adequate end-tidal CO<sub>2</sub> waveform.

The tube was secured, and an uncomplicated thoracoscopic repair was performed, revealing a large, cephalad takeoff Gross Type C (Vogt IIIb) fistula.

### Discussion

Many pediatric anesthesia and pediatric surgery publications provide illustrations of the tracheoesophageal fistula classification, many of which schematic by nature. A classic schematic illustration of a type C fistula (figure A) may give a somewhat wrong impression of the distances and the angles between the trachea and the esophagus, suggesting an almost perpendicular insertion of the fistula to the trachea, making esophageal intubation almost impossible.

As an esophageal intubation via a large fistula is possible and may be fatal if misdiagnosed (3), we suggest that:

- A more anatomically accurate illustration (Figure B) may provide practitioners a better understanding of the anatomical structures, and may enable better airway management and response to adverse events.
- This very rare but potentially fatal adverse condition must be kept in mind by those practicing neonatal anesthesia.
- In such extreme circumstances we advocate ventilation while applying external pressure to the abdomen to minimize gastric insufflation, and either extubation and re-intubation with tracheal flexion, or careful withdrawal of the ETT into the trachea and repositioning.

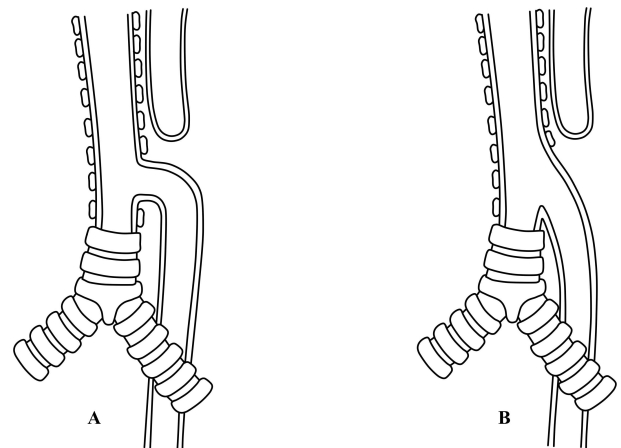


Figure A-B. A schematic drawing of a Gross Type C (Vogt IIIb) esophageal atresia and tracheoesophageal fistula. A: Classic illustration. B: A more anatomically accurate illustration.

### References

1. Taneja B, Saxena KN. Endotracheal intubation in a neonate with esophageal atresia and trachea-esophageal fistula: pitfalls and techniques. *Journal of neonatal surgery*. 2014;3:18.
2. Broemling N, Campbell F. Anesthetic management of congenital tracheoesophageal fistula. *Paediatric anaesthesia*. 2011;21:1092-9.
3. Alabbad SI, Shaw K, Puligandla PS, Carranza R, Bernard C, Laberge JM. The pitfalls of endotracheal

intubation beyond the fistula in babies with type C esophageal atresia. *Seminars in pediatric surgery*. 2009;18:116-8.